



WATS^{3D}[®]

The New Standard of Care

**Screening for Barrett's Esophagus
Surveillance of Barrett's Esophagus**

NOW INCLUDED IN GI STANDARD OF PRACTICE GUIDELINES

Release Date: August 19, 2019

WATS^{3D} Included in the ASGE Standard of Practice Guidelines for the Screening for and Surveillance of Barrett's Esophagus

GUIDELINE CLINICAL QUESTION:

In patients with known or suspected BE, what is the role of WATS^{3D} (Wide Area Transepithelial Sampling with computer-assisted 3-Dimensional analysis) in increasing the rate of dysplasia detection?

ASGE RECOMMENDATION:

In patients with known or suspected BE, the new guideline includes a recommendation for using WATS^{3D} in addition to white light endoscopy (WLE) with Seattle protocol biopsy sampling compared to WLE with Seattle protocol biopsy sampling alone.

New results published in
Gastrointestinal Endoscopy*

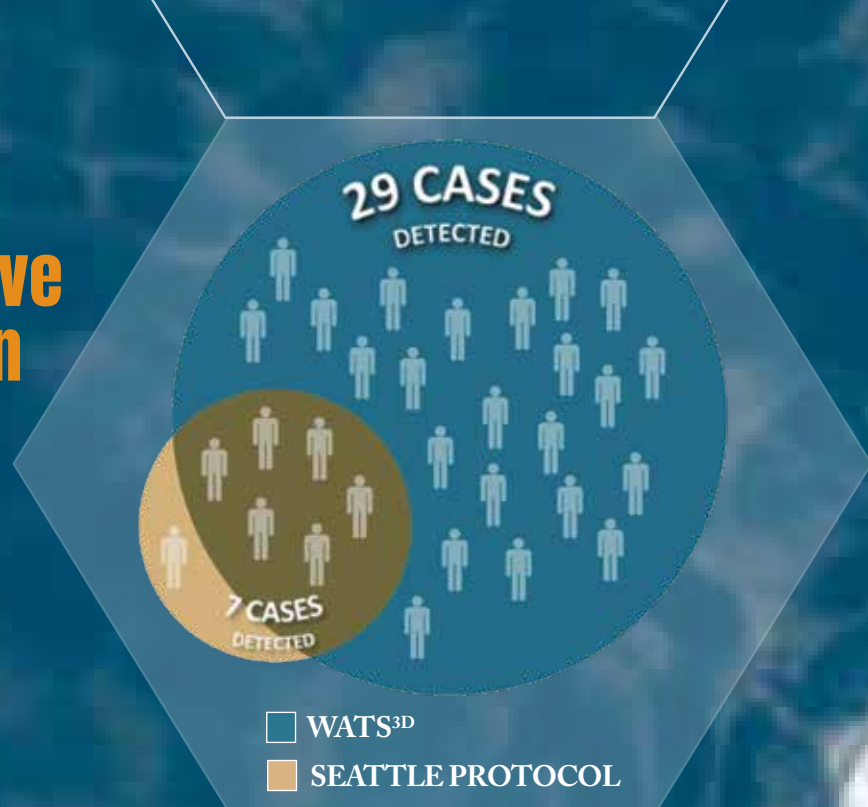
WATS^{3D} is 4x more effective in detecting HGD/EAC than the Seattle Protocol.

STUDY DESIGN

- 16 major academic GI centers participated
- Double-blind, randomized, crossover study
- 160 high-risk patients undergoing BE surveillance
- WATS^{3D} and Seattle Protocol 4-quadrant FB every 1-2 cm

STUDY AUTHORS

Prashanth R. Vennalaganti MD	University of Kansas School of Medicine, Kansas City, KS
Julian Abrams, MD, MPH	Columbia University School of Medicine, New York, NY
Ram Chuttani, MD	Beth Israel Deaconess Medical Center, Boston, MA
Glenn Eisen, MD, MPH	Stanford University, Palo Alto, CA
Gary W. Falk, MD, MS	University of Pennsylvania School of Medicine, Philadelphia, PA
Lauren B. Gerson, MD	Stanford University, Palo Alto, CA
John R. Goldblum, MD	Cleveland Clinic, Cleveland, OH
Seth A. Gross, MD	New York City Langone Medical Center, New York, NY
Neil Gupta, MD, MPH	Loyola University Medical Center, Maywood, IL
Gregory B. Haber, MD	New York City Langone Medical Center, New York, NY
Anthony Infantolino, MD	Thomas Jefferson University School of Medicine, Philadelphia, PA
Prasad G. Iyer, MD, MS, MPH	Mayo Clinic, Rochester, MN
David A. Johnson, MD	Eastern VA Medical School, Norfolk, VA
Vivek Kaul, MD	University of Rochester, Rochester, NY
Shivangi Kothari, MD	University of Rochester, Rochester, NY
Charles J. Lightdale, MD	Columbia University School of Medicine, New York, NY
Douglas K. Pleskow, MD	Beth Israel Deaconess Medical Center, Boston, MA
Felice Schnoll-Sussman, MD	Weill Cornell Medical Center, New York, NY
Nicholas J. Shaheen, MD	University of North Carolina School of Medicine, Chapel Hill, NC
Michael S. Smith, MD	Temple University School of Medicine Philadelphia, PA
Kenneth K. Wang, MD	Mayo Clinic, Rochester, MN
Yaxia Zhang, MD	Cleveland Clinic, Cleveland, OH
Prateek Sharma, MD	University of Kansas School of Medicine, Kansas City, KS

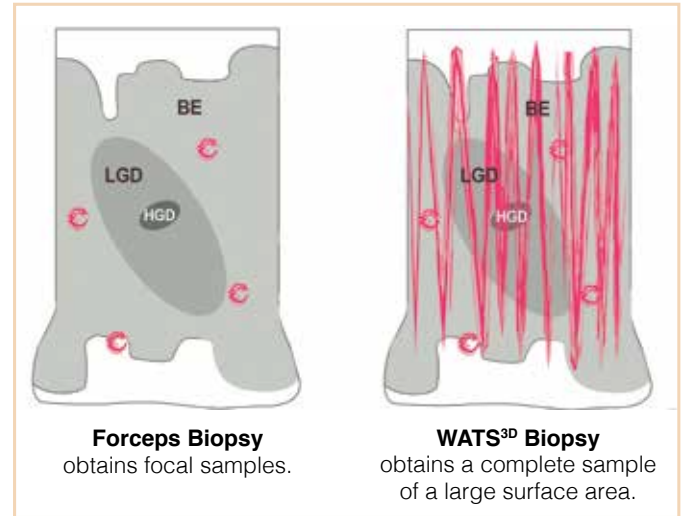


*Vennalaganti PR, Eisen G, Falk GW, et al.
Increased Detection of Barrett's Esophagus-
Associated Neoplasia Using Wide Area
Transepithelial Sampling in Conjunction with
4-Quadrant Forceps Biopsies: Final Results
from a Multi-Center, Prospective, Randomized
Trial. Gastrointestinal Endoscopy.
<http://dx.doi.org/10.1016/j.gie.2017.07.039>

BREAKTHROUGH SAMPLING

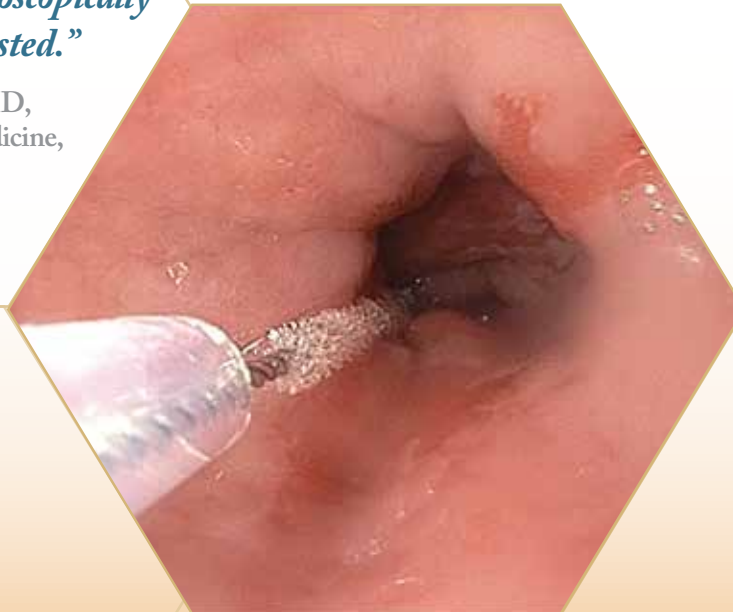Finally, you can address the sampling limitations of random forceps biopsy

- Barrett's esophagus (BE) and dysplasia are often missed with 4-quadrant biopsies
- Wide area sampled by WATS helps find abnormality located between forceps biopsy samples
- WATS wider area sample sharply increases routine detection of BE and dysplasia (see bar chart)



“At the current time, endoscopists rely solely on taking small random forceps biopsies, at 1-2 cm intervals, leaving more than 96% of the endoscopically suspect area completely untested.”

— Prashanth R. Vennalaganti, MD,
University of Kansas, School of Medicine,
Kansas City, KS



BREAKTHROUGH ANALYSIS

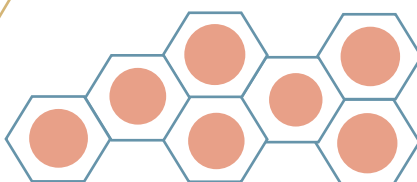
3D imaging yields critical diagnostic information – including the *en face* view of the gland

- If standard tissue sectioning were applied to a WATS sample, critical diagnostic information would be destroyed
- Analogous to a CAT scan, WATS^{3D} computer imaging synthesizes up to 50, 2D optical slices of each 3 micron focal plane into a single 3D image of the entire 150 micron thick specimen
- This computer synthesized WATS 3D image presents to the pathologist the *in vivo*, *en face* view of the gland — allowing for a definitive diagnosis of dysplasia in cases which may otherwise be reported as “indefinite”

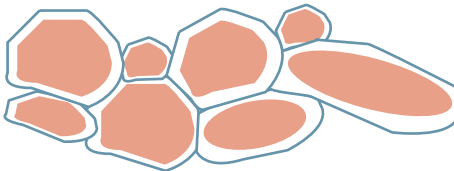
How capturing the *en face* view of the gland helps to eliminate “Indefinite for Dysplasia” Reports:

A WATS^{3D} sample is 50x thicker than a standard 3 μ thick histopathology slide

150 μ




Non-dysplastic epithelium is characterized by a regular honeycomb pattern



Effacement of this honeycomb is a characteristic sign of dysplasia

WATS^{3D} computer synthesis of 50, 2D “optical slices” forms an *in vivo* 3D image of the uncut glandular surface.



BREAKTHROUGH CONSISTENCY

Computer assisted technology yields sharply higher inter-observer agreement among pathologists¹

- WATS^{3D} proprietary algorithm and neural network highlights the most suspicious areas on this computer synthesized image for consistent pathologist review

Kappa values in the diagnosis of BE and dysplasia

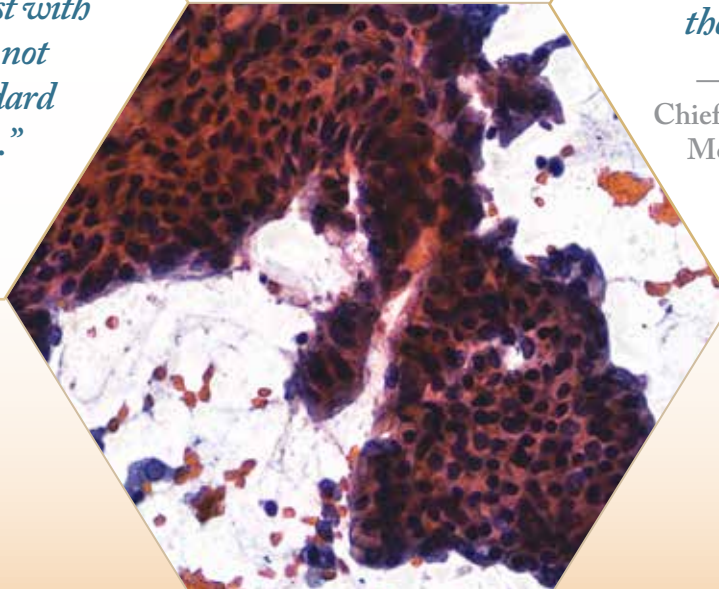
WATS ^{3D} Overall	.86
• HGD/EAC	.95
• IND/LGD	.74
• NDBE	.88
Standard Histopathology	.30

“WATS^{3D} not only addresses the sampling error inherent in relying on random forceps biopsies, its three-dimensional computer assisted analysis of the tissue sample provides the GI pathologist with diagnostic information that is not typically available using standard tissue based histopathology.”

— Robert D. Odze, MD, FRCPC

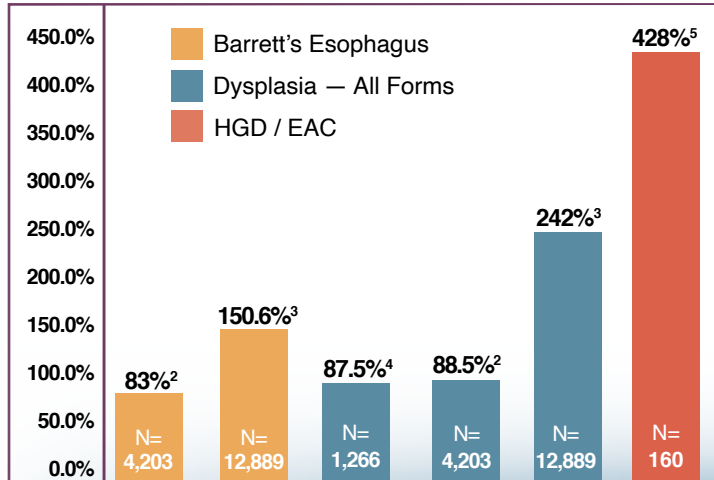
“These robust data demonstrate we have a tool that markedly improves our ability to detect dysplasia and cancer within Barrett’s well beyond the error-prone Seattle protocol.”

— Michael S. Smith, MD, MBA,
Chief of Gastroenterology and Hepatology,
Mount Sinai West and Mount Sinai
St. Luke’s Hospitals, NY



BREAKTHROUGH DATA

Increased Diagnostic Yield with Adjunctive Use** of WATS^{3D}



**WATS as an adjunct to standard forceps biopsy compared with standard forceps biopsy alone

“I see no reason why every academic and community gastroenterologist should not be using this rapidly performed, easily implemented procedure today to improve the diagnosis of Barrett’s esophagus and dysplasia, so patients can be directed to appropriate endoscopic surveillance or therapy to prevent esophageal cancer.”

— Dr. Charles Lightdale, MD,
Columbia University Medical Center,
New York

**Overcome Random Biopsy
Sampling Error –
Starting With Your Next EGD.**

Please contact us today at 1-845-777-7000
or wats3d@cdxdiagnostics.com to learn how easy
it is to let WATS^{3D} help your next EGD
be far more reliable.

WATS^{3D}



¹Vennalaganti PR, Kanakandi VN, Gross SA, et al.

Inter-observer agreement among pathologists using wide-area transepithelial sampling with computer-assisted analysis in patients with Barrett's esophagus. *Am J Gastroenterol.* 2015;110(9):1257-1260

²Gross SA, Smith M, Ali R, Kaul V on behalf of US Collaborative WATS3D Study Group.

Increased detection of Barrett's esophagus and esophageal dysplasia using transepithelial brush biopsy with three dimensional computer-assisted tissue analysis: a prospective multi-site community-based study. *United Eur Gastroenterol J.* 2015;3(5S):A103.

³Ikonomi EP, Bhuta R, Iorio N, et al.

Transepithelial brush biopsies with computer-assisted 3-dimensional analysis markedly improve detection of Barrett's esophagus and dysplasia: interim analysis from a prospective multi-center community-based study. *Am J Gastroenterol.* 2015;110(Suppl 1):S728.

⁴Johansen JF, Frakes J, Eisen D, et al.

Computer-assisted analysis of abrasive transepithelial brush biopsies increases the effectiveness of esophageal screening: a multicenter prospective clinical trial by the EndoCDx Collaborative Group. *Dig Dis Sci.* 2011;56(3):767-772

⁵Vennalaganti PR, Eisen G, Falk GW, et al.

Increased Detection of Barrett's Esophagus-Associated Neoplasia Using Wide Area Transepithelial Sampling in Conjunction with 4-Quadrant Forceps Biopsies: Final Results from a Multi-Center, Prospective, Randomized Trial. *Gastrointestinal Endoscopy.*
<http://dx.doi.org/10.1016/j.gie.2017.07.039>



Two Executive Boulevard, Suffern, New York 10901 • www.wats3d.com • Client Services (845) 777-7000